



# Robotic-assisted coronary artery bypass grafting: how I teach it

Francis P. Sutter<sup>1</sup>, MaryAnn C. Wertan<sup>1</sup>, Danielle Spragan<sup>1</sup>, Yoshiyuki Yamashita<sup>2</sup>, Serge Sicouri<sup>2</sup>

<sup>1</sup>Department of Cardiac Surgery Research, Lankenau Institute for Medical Research, Main Line Health, Wynnewood, PA, USA; <sup>2</sup>Department of Cardiac Surgery, Lankenau Heart Institute, Lankenau Medical Center, Main Line Health, Wynnewood, PA, USA

Correspondence to: MaryAnn C. Wertan, RN. Division of Cardiac Surgery, Lankenau Medical Center, 100 Lancaster Avenue, 356 Lankenau, MOB East, Wynnewood, PA 19096, USA. Email: WertanM@mlhs.org.

The first robotic cardiac operation was performed more than two decades ago. This paper describes the distinct steps and components necessary for teaching robotic-assisted minimally invasive direct coronary artery bypass (R-MIDCAB). It also provides a general overview of the surgical robotic setup and ways to troubleshoot potential complications. The focus of robotic training is not only on the surgeon but includes an entire dedicated cardiac team and administrative institutional support. This team approach ensures that R-MIDCAB can be performed safely and reproducibly. Meticulous planning, incremental learning, and teamwork are the main factors leading to program success and optimal patient outcomes. Robotic-assisted internal mammary artery (IMA) harvesting and coronary revascularization via a small, anterior mini-thoracotomy has provided an alternative to sternotomy in selected patients with coronary artery disease (CAD). Benefits include less postoperative atrial fibrillation, fewer blood transfusion, less time in the operating room (OR), less ventilatory support, fewer strokes, decreased intensive care unit stay and shortened postoperative length of stay all of which manifests as a decrease in institutional resource utilization. Recent data show that R-MIDCAB and hybrid coronary revascularization provides good long-term outcomes. In addition to patient satisfaction, there is an additional overall cost benefit to R-MIDCAB over traditional sternotomy coronary artery bypass grafting (CABG), secondary to decreased hospital length of stay. Robotically harvesting the IMA, operating on a beating heart, and performing anastomoses through a small incision all require advanced training and incremental learning. Increased experience generally leads to shortened surgical times and fewer complications.

**Keywords:** Robotic-assisted coronary artery bypass grafting (robotic-assisted CABG); learning curve; minithoracotomy; coronary revascularization; minimally invasive direct coronary artery bypass (MIDCAB)



Submitted Mar 05, 2024. Accepted for publication Jun 10, 2024. Published online Jul 29, 2024.

doi: 10.21037/acs-2024-rcabg-0033

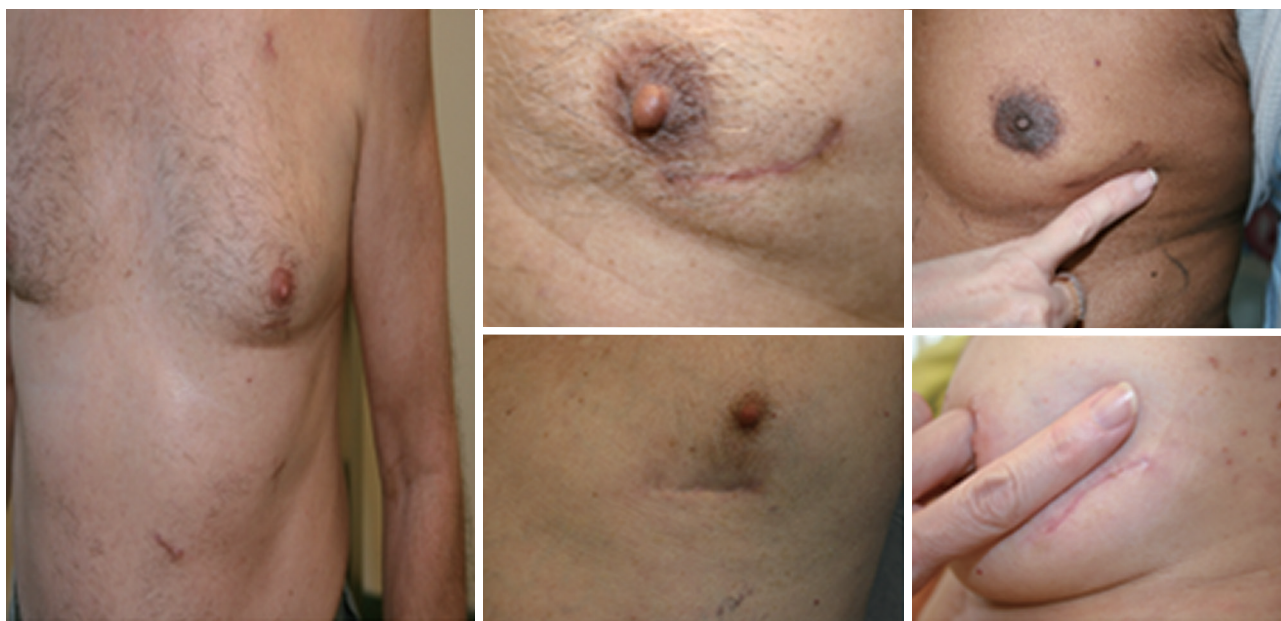View this article at: <https://dx.doi.org/10.21037/acs-2024-rcabg-0033>

## Introduction

Robotic-assisted coronary revascularization via a small, anterior mini-thoracotomy (*Figure 1*) using the da Vinci Intuitive Surgical System (Intuitive Surgical, Inc., Sunnyvale, CA, USA), has provided an alternative treatment method for patients with coronary artery disease (CAD) (1-3). For appropriately selected patients, benefits include less postoperative atrial fibrillation, fewer blood transfusion, less time in the operating room (OR), less ventilatory support, fewer strokes, decreased intensive care unit stay and shortened postoperative length of stay (4); all

of which manifests as a decrease in institutional resource utilization (4). A recent study over a 15-year period described the clinical outcomes of 2,280 patients who underwent robotic-assisted coronary artery bypass grafting (CABG) (4). The data show that robotic-assisted minimally invasive direct coronary artery bypass (R-MIDCAB) and hybrid coronary revascularization (R-MIDCAB combined with percutaneous coronary intervention with stents) provides good long-term outcomes in patients (5,6).

In addition to patient satisfaction, there is an additional overall cost benefit to R-MIDCAB over traditional sternotomy CABG (7) secondary to decreased hospital



**Figure 1** Minimal scars following robotic-assisted CABG procedures. CABG, coronary artery bypass grafting.

length of stay. R-MIDCAB is the collective term for CABG procedures performed through small incisions as an alternative to median sternotomy. Harvesting the IMA robotically, operating on a beating heart, and performing anastomoses through a small incision all require advanced training and incremental learning. Increased experience generally leads to shortened surgical times and fewer complications (3,4). R-MIDCAB is a challenging procedure, which requires a dedicated surgical team to start this journey. This paper aims to describe the distinct steps and components necessary for teaching R-MIDCAB. It also provides a general overview of the surgical robotic setup and ways to troubleshoot potential complications that will lead to successful surgical outcomes.

### **Creating the team optimal qualifications: institution, team, and surgeon**

Implementation of a successful advanced R-MIDCAB program is achieved through strategic planning, clinical training, and expert support.

#### **Institution/administrative support**

Full administrative support is needed for starting a robotic program, including purchasing the da Vinci robotic system

and all necessary supplies. Additionally, dedicated OR staff and assistants will need to be trained to ensure a seamless transition to performing robotic cases. Regular access with dedicated robotic time is essential to overcome the initial learning curve associated with utilizing the robot. Cardiology engagement is yet another important aspect of robotic surgery, as interventional cardiologists are crucial partners for a successful program. Various distinct CABG procedures options are available, including conventional full sternotomy, either on or off pump, as well as robotic-assisted CABG +/- hybrid coronary revascularization. Therefore, interdisciplinary discussions between surgeons and cardiologists will determine the best course of action for each specific patient. Weekly coronary revascularization team meetings should be arranged. Moreover, it is important to discuss various revascularization options with the patient, as there are risks, benefits, and alternatives to each type of procedure. Informed consent should include the possibility of conversion to traditional sternotomy if surgery cannot be completed safely through minimally invasive means.

#### **Creating the team**

The initial task is to create a dedicated operative team, including nursing staff, surgical assistants, and

anesthesiologists. Success in the operative theater is dependent on high levels of engagement and support. Operative nursing staff need to be trained in how to use and troubleshoot the da Vinci system. Surgical bedside assistants are vitally important as they will be responsible for both instrument exchanges and robotic arm positioning and adjustments. Anesthesiologists should be comfortable with off-pump coronary cases, in addition to the demands of dealing with an insufflated thorax in robotic cases.

Perfusionists need to be immediately available if cardiopulmonary bypass is required. These individuals should all be included in formalized robotic training to achieve mastery of the system and instruments. The bedside assistant must be able to anticipate the key portions of the operation, and they serve as important collaborators during the case. The surgical assistant must also be comfortable assisting with off-pump coronary surgery cases, as creating the anastomosis is the second crucial element of the operation after robotic-assisted takedown of the left IMA (LIMA).

### Surgeon experience & training

R-MIDCAB mastery has a threshold of approximately 100 cases. As previously mentioned, development of a heart team approach is essential, and establishing rapport with a core team is key to successful adoption. Additional experience, is identified below:

- (I) Extended off-pump bypass grafting experience, with at least 50 off-pump cases as primary operator to establish proficiency in off-pump CABG.
- (II) Completion of the required training modules per Intuitive Surgical, Inc. to become comfortable with the many components of the da Vinci surgical system. This will entail several training modules and simulation sessions, to thoroughly understand all components of the operating system. Didactic sessions as well as cadaveric simulation sessions will improve the surgeon's comfort level with the robot. Additionally, observing a live case with an experienced robotic surgeon is extremely helpful.
- (III) The surgeon serves as the bedside assistant for at least 20 cases, if possible, even if not on cardiac cases, where the surgeon will learn port placement, participate in instrument exchanges and troubleshooting.
- (IV) After gaining a level of comfort with simulation

and bedside assisting, the surgeon then moves to the operating console to gain experience with IMA harvest.

Ideally, there should be opportunities to train in robotic IMA harvesting, even during sternotomy CABG. Typically, the use of three 8-mm port holes results in less discomfort compared to the Rultract<sup>®</sup> Skyhook Retractor (Rultract Incorporated, Cleveland, OH, USA), generally used to retract the chest wall during IMA harvesting. However, this approach necessitates prior discussions with the administration, system chief, and the patient, and should be appropriately documented in the patient's medical record before the surgery.

### Patient selection: indications and contraindications of robotic-assisted CABG surgery

#### Indications

The main indications for R-MIDCAB focus on targeting a severely diseased left anterior descending artery (LAD) that can be accessed via a small, left anterior thoracotomy:

- (I) Severe ostial LAD disease;
- (II) Long LAD lesions, suboptimal for stenting;
- (III) Chronic total occlusions of the LAD;
- (IV) Patients with severe CAD and advanced age or comorbidities, following heart team discussion, especially with hybrid coronary revascularization LIMA to LAD, and stenting to non-LAD lesions;
- (V) Complex disease involving LAD and diagonal.

#### Contraindications

Contraindications of robotic-assisted cardiac surgery include:

- ❖ Absolute contraindications:
  - ◆ Previous pleural symphysis;
  - ◆ Extensive lung surgery;
  - ◆ Prior use or injury of both internal mammary arteries.
- ❖ Relative contraindications:
  - ◆ Severe obesity;
  - ◆ Significant heart enlargement (insufficient space between anterior heart surfaces and posterior chest wall);
  - ◆ Chest wall deformity/severe pectus excavatum;
  - ◆ Diffuse distal coronary disease;

- ◆ Intramyocardial coronaries arteries;
- ◆ Severe pulmonary disease (intolerance to single lung ventilation).

### Incremental learning

There are several components for successfully achieving R-MIDCAB mastery including proper port placement, robotic harvesting of the internal mammary, and performing off-pump anastomosis. Crucial elements of off-pump CABG include familiarity with manipulating the ischemic heart, ischemic preconditioning, shunt placement, stabilizer placement and finally performing arterial anastomosis on a beating heart. The ability to maneuver the ischemic heart cannot be overemphasized, as creation of the anastomosis often requires the heart to be repositioned a few times for optimal visualization. For surgeons accustomed to on-pump CABG, practice performing the LIMA to LAD anastomosis, with the heart beating, while still on-pump, can be quite useful. Learning to sew from the left is also important.

### Comprehensive team training

It is important to observe experienced robotic surgeons during live cases, as there are numerous nuances to each case that can be incorporated into your own practice. Once ready to embark on robotic cases, the entire team should perform several “dry runs” with the assistance of an Intuitive Surgical, Inc. representative. Most elements of the case should be simulated including: docking the robot and ensuring all instruments are available (including for traditional sternotomy), ensuring staff familiarity and comfort. Anesthesiologists should be included in these simulation sessions as well as they play a crucial role in the management of the patient.

### R-MIDCAB surgical procedures—general considerations

Some general considerations and troubleshooting tips are described below.

#### Anesthesia awareness participation

Normothermia is a priority, having been achieved before induction of anesthesia and warming is maintained throughout the entire operation. An aggressive attempt to keep the patients warm is initiated in the immediate preoperative and

intraoperative periods (8). The anesthesiologist will selectively ventilate the right lung, while isolating the left as dictated by the surgeon. Anesthesiologist should prepare for CO<sub>2</sub> insufflation of the thoracic cavity (inducing an iatrogenic tension pneumothorax) and its associated hypotension. The anesthesiologist needs to be aware of the possible restricted robotic arm movement which may necessitate repositioning of the head & neck of the patient.

#### Patient positioning

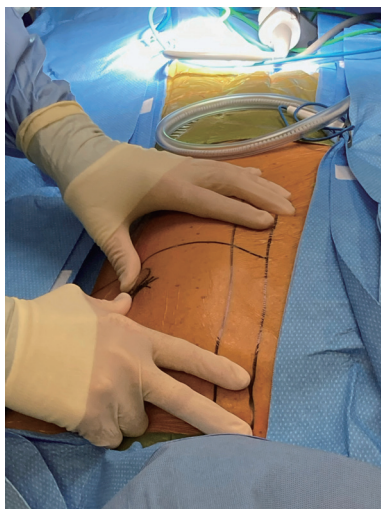
Position the patient on the operative table by aligning the left side of their body on the table's edge such that the left shoulder overhangs slightly. This positioning allows bedside assistant to apply gentle pressure on the left shoulder which increases the arm's maneuverability. Frequently during dissection of the distal IMA, the superior port will be significantly restricted by the anterior location of the shoulder. Anesthesiologist & bedside assistants play a key role in maintaining the free movement of the upper robotic arm. Similarly, gentle pressure on the costal margin can accomplish the same movement for the inferior robotic arm.

#### Set up and draping

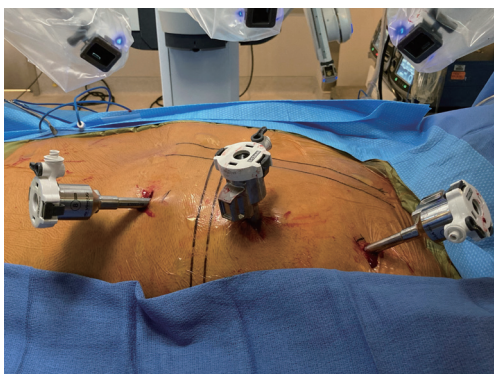
External defibrillator pads are placed on the patient and positioned anteriorly over the right pectoralis major and posteriorly underlying the heart. It is important to have this prepared for use with the adequate intensity for external defibrillation (150–200 Joules). Plan the incision before draping: draw landmarks at midline sternum (*Figure 2*), LIMA location, diaphragm (typically at the step off the sternum and xiphoid), and locations for inferior and superior port sites. Avoid making an inframammary crease incision, which delays healing. Manipulation of the female breast will be required to ensure the best possible incision, usually retracting the breast as laterally as possible, and securing this position with 3 M™ Steri-Drape™ (3M USA, USA), works best. For women, make an incision through the breast and generally through left lower inner quadrant.

#### Know the exact target

Try to visualize the best port placement and endoscopic port placement prior to making any incision. Usually, the endoscopic port becomes the thoracotomy. The optimal thoracotomy will be dependent upon the target vessel:



**Figure 2** Preparing for robotic-assisted surgery. Drawing landmarks.



**Figure 3** Robotic-assisted CABG set-up. CABG, coronary artery bypass grafting.

LAD, diagonal, and/or ramus intermedius, as well as the size of the heart seen on chest front and lateral chest X-ray (CXR) or computed tomography (CT) scan. Generally, it is better for the thoracotomy to be more lateral and inferior as it is difficult to push the heart laterally or superiorly.

### Docking of the robot

#### *Endoscopic port placement and general setup*

Figure 3 shows the general set up of Robotic-assisted CABG.

Always stop ventilation during placement of the endoscopic port. When first learning R-MIDCAB, place

endoscopic port more lateral to prevent injury to the heart; as experience grows, the endoscopic port can be placed more medially. After the endoscope and instruments have been placed, another method to enhance anterior/posterior operative space is to release the medial and anterior pericardial fat attachments from the chest wall, which further allows the CO<sub>2</sub> to depress the heart posteriorly. The endoscopic port will eventually be enlarged as part of anterior thoracotomy, so placement is critical.

#### *Opening the pericardium*

Open the pericardium lateral to pulmonary artery directly over the LAD. Wide opening of the pericardium is critical for several reasons. First, when operating through a small incision, this approach prevents pericardial fat and the pericardial border from obstructing the surgical view, ensuring that the target area remains the sole focus. Second, a wider pericardial opening reduces the risk of major bleeding and postoperative tamponade. Finally, it ensures proper drainage from the right side of the pericardial cavity; a lesson learned from early experience with delayed inflammatory tamponade on the right side.

### The IMA

The general surgical rule of “not dissecting into a hole” is equally relevant to robotic-assisted LIMA harvesting. Slowly dissect the length of LIMA in small increments, to avoid pulling on any one area of the LIMA. During skeletonization, retaining a few anterior attachments on the chest wall will prevent injury until dissection is complete. LIMA manipulation can result in spasticity and a propensity for clot formation, thus leaving larger branches intact distally promotes greater blood flow through the LIMA to combat the procoagulant effects of manipulation. Beware: the lack of haptic feedback can result in excessive traction or force being applied to the vessel, thereby resulting in the undesired dissection of the LIMA wall. Nothing is worse than completing a LIMA takedown, proceeding to CABG, and discovering a nonfunctional LIMA conduit. LIMA dissection is generally performed from just distal to the intersection of the phrenic nerve and LIMA, until the bifurcation. Do NOT risk injury to the phrenic nerve!

Using higher wattage on the cautery allows for faster dissection but increases risk of burning a hole through the LIMA, while lower wattage will cause a superficial non-penetrating injury. In my experience, the vast majority of

IMA dissections, can be performed with an equal amount of blunt and sharp dissection. Additionally, to avoid avulsing branches of the IMA, one should always dissect away from the IMA. Traditionally, the LIMA has been harvested as a pedicle (“*en bloc*”) under direct vision. Skeletonized IMA technique is used for R-MIDCAB because, invariably, the pedicle dissection leads to a cut in an IMA branch and the branch retracts back into the pedicle. It is then a delicate dissection to control the bleeding branch without damaging the IMA. While skeletonizing the LIMA, the surgeon and bedside assistants should constantly watch for the “pulsatility” of the LIMA to avoid inadvertent damage to IMA. Bilateral IMA harvest begins with the right IMA. When initially dissecting across the sternum to the right IMA, maintain a plane of dissection directly on the posterior sternal border.

### Managing complications

#### *Bleeding during IMA dissection*

Be meticulous in controlling any bleeding. Bleeding stains tissue and makes visualization difficult during further dissection. If bleeding occurs, use robotic instruments to apply gentle pressure for a few minutes to create a bloodless field, thus allowing for subsequent treatment of the bleeding branch with a clip or cautery.

#### *Arrhythmia*

Proceed with caution with cautery and proximity to myocardium, as the heat can induce tachyarrhythmias, including ventricular fibrillation. Lidocaine bolus should be readily available. Should arrhythmia occur, remove all robotic ports, defibrillate with external pads, powered to 150–200 Joules. Remind anesthesia to reinflate the left lung to best defibrillate.

#### *Cardiac puncture*

Accidental cardiac puncture can occur during port placement without adequate visualization, stabilizer placement, or during instrument exchanges. Direct pressure should be applied as able to allow the anesthesia team to properly resuscitate before attempting repair. Be prepared to perform sternotomy, as well as cannula for fem-fem bypass, if necessary to control the bleeding.

#### *Compromised circulation*

Plan for easy and direct access to cardiopulmonary bypass supplies and an emergency tray with sternotomy and fem-

fem bypass essentials should be readily available.

#### *Avoid post operative bleeding*

Meticulous hemostasis is necessary prior to robot removal, particularly a thorough inspection through endoscope as each port is removed.

#### *Pain management*

Optimization of postoperative pain management is performed by infiltration of the incision, muscles and drainage sites using a local anesthetic, a mixture which includes 30 mL lidocaine w/epinephrine 0.5%—1:200,000, 30 mL bupivacaine 0.25% and 60 mL ropivacaine w/epinephrine 0.2%—1:600,000. This pain management protocol has been shown to facilitate intraoperative extubation of the patient (8). Intravenous narcotics and ketorolac are used with the dosage of the latter modified based on the patient’s age and renal status. In our experience, 88% of all patients are extubated in the OR.

### Conclusions

Since 2005, we have performed 5,903 CABG procedures, through December 31, 2023, and 46% were robotic-assisted cases, with 1.8% of conversion to sternotomy, which in most instances were related to damaged or inadequate internal mammary. Thirty-day mortality was 1.2%. R-MIDCAB is a safe, efficacious, and reproducible procedure, offering an alternative to sternotomy in carefully selected patients. Meticulous planning, incremental learning and teamwork are the main factors leading to success. Robotic surgery training can be safely implemented in a minimally invasive surgery training program. A gradual introduction of robotic technique maximizes the learning experience and minimize the potential for adverse outcomes.

### The American Association for Thoracic Surgery (AATS) Foundation Cardiac Surgical Robotic Fellowship

The Cardiac Surgical Robotics Program (<https://www.aats.org/foundation/cardiac-surgical-robotic-fellowship>) provides an advanced educational experience in robotic cardiac surgery for North American cardiac surgeons who will bring expanded knowledge back to their home institution. Awardee pre-requisite training before beginning the fellowship include: (I) system training: one day systems training at an Intuitive training facility (preferably accompanied by requested proctor); (II)

cadaver laboratory training: one cadaver lab while at training facility; (III) procedure training: observation—a minimum of two cardiac robotic cases at selected well-established training center with their experienced surgeon proctor; (IV) robotic simulation; (V) successful completion of a robotic simulation skills curriculum; (VI) passing test score in robotic ergonomics, accuracy, and speed; (VII) onsite proctoring: five patient operations; (VIII) case video proctoring: proctors to review the case videos of three patient operations to provide feedback to the awardee; (IX) commitment by awardee to complete 50 cases and submit outcomes back to AATS Foundation; (X) hold remote training sessions with their mentor. A recent consensus review (9) recommends a clinical experience for the robotic surgeon of 250 career cases of coronary revascularization as primary operator (on or off pump) with an observed to expect (O/E) <1, of O/E of which 50 should be off pump.

#### **Society of Thoracic Surgeons/Thoracic Surgery Foundation (STS/TSF) Advanced Robotic Cardiac Surgery Fellowship**

This advanced fellowship opportunity will be awarded to a surgeon and their institution to support and facilitate the successful initiation of a high quality robotic cardiac surgery program at his/her home institution. Applicants must attend the STS Workshop on Robotic Cardiac Surgery, meet specific requirements confirming institutional support and resources, and have experience performing CABG. The fellow will be assigned to an STS proctor, who will then serve as the primary mentor/sponsor and assist the fellow with five robotic cases, at the fellow's institution. This fellowship is supported by the generosity of Intuitive. Surgeon applicant minimum requirements with respect to Training & Practice and Clinical Experience, as per "Contemporary robotic cardiac surgical training" by Badhwar *et al.* (9), appropriate for the fellowship tract: for the Robotic Revascularization Program—(I) American Board of Thoracic Surgery accreditation or equivalent; (II) three years of independent attending-level clinical practice, and/or a minimum one-year post-graduate robotic cardiac fellowship with robotic revascularization concentration; (III) 250 career cases of coronary revascularization as primary operator (on- or off- pump) with an O/E of  $\leq 1$ , of which 50 should be off-pump.

#### **Acknowledgments**

*Funding:* None.

#### **Footnote**

*Conflicts of Interest:* F.P.S. participates with Speakers Bureau for Intuitive Surgical, Inc. The other authors have no conflicts of interest to declare.

*Open Access Statement:* This is an Open Access article distributed in accordance with the Creative Commons Attribution-NonCommercial-NoDerivs 4.0 International License (CC BY-NC-ND 4.0), which permits the non-commercial replication and distribution of the article with the strict proviso that no changes or edits are made and the original work is properly cited (including links to both the formal publication through the relevant DOI and the license). See: <https://creativecommons.org/licenses/by-nc-nd/4.0/>.

#### **References**

1. Sutter FP, Berry T, Wertan MC. Precision incision: robotic coronary revascularization via 3.9-cm minithoracotomy. *Innovations (Phila)* 2012;7:223-8.
2. Sutter FP, Wertan MC. Robotic-assisted bilateral internal thoracic artery harvest. *Ann Cardiothorac Surg* 2018;7:704-6.
3. Van den Eynde J, Vaesen Bentein H, Decaluwé T, et al. Safe implementation of robotic-assisted minimally invasive direct coronary artery bypass: application of learning curves and cumulative sum analysis. *J Thorac Dis* 2021;13:4260-70.
4. Dokollari A, Sicouri S, Erten O, et al. Long-term clinical outcomes of robotic-assisted surgical coronary artery revascularisation. *EuroIntervention* 2024;20:45-55.
5. Torregrossa G, Sá MP, Van den Eynde J, et al. Robotic-assisted versus conventional off-pump coronary surgery in women: A propensity-matched study. *J Card Surg* 2022;37:3525-35.
6. Torregrossa G, Sá MP, Van den Eynde J, et al. Robotic hybrid coronary revascularization versus conventional off-pump coronary bypass surgery in women with two-vessel disease. *J Card Surg* 2022;37:501-11.
7. Dokollari A, Sicouri S, Prendergrast G, et al. Robotic-Assisted Versus Traditional Full-Sternotomy Coronary Artery Bypass Grafting Procedures: A Propensity-Matched Analysis of Hospital Costs. *Am J Cardiol* 2024;213:12-9.

8. Gobran SR, Goldman S, Ferdinand F, et al. Outcomes after usage of a quality initiative program for off-pump coronary artery bypass surgery: a comparison with on-pump surgery. *Ann Thorac Surg* 2004;78:2015-21; discussion 2021.
9. Badhwar V, Wei LM, Geirsson A, et al. Contemporary robotic cardiac surgical training. *J Thorac Cardiovasc Surg* 2023;165:779-83.

**Cite this article as:** Sutter FP, Wertan MC, Spragan D, Yamashita Y, Sicouri S. Robotic-assisted coronary artery bypass grafting: how I teach it. *Ann Cardiothorac Surg* 2024;13(4):346-353. doi: 10.21037/acs-2024-rcabg-0033